

# The Diagnostic Value of Biometric Instruments

John Charles Radke & Gerardo Ruiz Velasco

## Chapter 1: JVA measurements of TMJ function

Table of contents	Page
The process of JVA	2
TMJ Vibration Waveforms	3
What about Manual Palpation?	4
The 2 <sup>nd</sup> Type of TMJ Vibration	4
Vibration Frequency Content	4
Ratio: > 300 Hz/ < 300 Hz	6
Median Frequency	6
Graphics Vs Numerics	6
Jaw Position at onset of vibration	6
Significance of numerical values	7
1. Intensity of vibration	
2. Significance of ROM	
3. Significance of > 300 Hz	
4. Significance of the Ratio	
5. Measure Noise function	
About the JVA Flow Chart	8
Indications for imaging	9
Criteria needed to recapture a disk	9
References	10
Key words and definitions	12
Appendix to chapter 1	13

- JVA Flow Chart
- Mechanics of marking records
- Masking a trace

### Abstract

Joint Vibration Analysis (JVA) is a method of recording the vibrations emanating from the TMJs in such a way that their analysis can contribute to the TMD diagnostic process. This chapter will describe the process of recording and analyzing TMJ vibrations. JVA is not intended to replace TMJ imaging, but rather to complement it. The relationship of JVA to patient report, the clinical exam and imaging is described. It is explained how the analysis of data from JVA can be very helpful when deciding whether MRI or CT would be more useful. When a JVA suggests that the TM joints are not damaged and functioning well, the added cost of MRIs or CBCT images may be avoided, minimizing the numbers of completely “normal” images taken. The significance of each of the JVA parameters is discussed. The JVA Flow Chart and its use is explained. The indications for imaging are reviewed and some suggestions are presented for when disk recapture may be possible. An appendix describes all of the mechanics of recording and analyzing JVA data.

## Chapter 1: Joint Vibration Analysis (JVA)

The two principle tenants of joint Vibration Analysis include; 1) that a normal adult temporomandibular joint is quiet during function and 2) that it operates smoothly throughout its normal *Range of Motion* (ROM), which averages 55 mm for males and about 5 mm less for females when opening to the maximum. (Gupta, Thumati & Radke, 2016; Kondrat, Sierpinska & Radke 2018; Lewis, Buschang & Throckmorton, 2001; Ishigaki, Bessette, Maruyama, 1993A). With the presence of hypermobility, a patient of either gender may open beyond 70 mm. It is widely considered that a ROM of less than 40 mm is likely to be a restricted one, but due to individual variability that is not a magic or absolute number (Linde & Isacson, 1990). Numerous factors affect the ROM; size of the jaws, relative mobility of the joints (one being relatively tight or loose jointed), the condition of the disk, etc. making it impossible to predict what should be the exact normal value for any individual. Irrespective of these limitations, JVA provides consistent useful information regarding the dynamic function of the TMJ. Since JVA indicates the dynamic function of the joint, it complements, rather than competes with the various imaging technologies that allow visualization of the morphology of the joint (Kondrat, Sierpinska & Golebiewska, 2012).

### The process of JVA

The JVA process starts with the recording of vibrations from the TMJ. It is necessary to record simultaneously from both joints, since vibrations from one joint can appear on the contralateral side. However, whenever that happens, a delay is present in the “echo,” as it is sometimes referred to (Salzman, 2018). Although the delay may be only 1 or 2 milliseconds, by using a sub-millisecond time resolution, by sampling at 2000 samples/second or even higher, it is possible to distinguish which side is originating (Widmalm, Williams & Yang, 1999). To avoid picking up noise from the environment, accelerometer



Figure 1. JVA accelerometers are held in place attached to a stereo headband. This allows precise placement of them over the coronoid notch bilaterally.

transducers can be placed directly over the joints and shielded from external noise. A silicone gel that matches the mechanical properties of the soft tissue over the TMJ can be used to increase the sensitivity to record vibrations with as little as one micron of amplitude (Christensen, 1992). A simple stereo headband is a convenient way to hold both the left and right transducers in place. See Figure 1. The transducers are located directly anterior to the tragus so the condyle moves under them bilaterally as the mouth is opened.

The vibration waveforms are amplified and then digitized, typically at 2,000 to 4,000 samples/second to prepare them for various computer software analyses. The BioPAK™ 9.0 program, (BioResearch Associates, Inc., Milwaukee, WI USA), written for Windows® (Microsoft, Inc., Redmond, WA USA) has been continuously developed since 1984, initially under the IBM old type Disk Operating System (DOS). BioPAK is currently compatible with Windows versions 7 to 10. Once the data have been digitized the files are also saved to hard disk for future reference. This allows comparing pre-treatment recordings with

post treatment recordings to document the real effects upon the TMJs of any treatment.

### TMJ vibration waveforms

As it happens there are just two main types of vibration waveforms emanating from the TMJ that are indicative of specific dysfunctions within the joint. When a disk displaces or reduces, partially or completely, it produces a short duration, relatively high amplitude vibration. (Ishigaki, Bessette & Maruyama, 1993B; Radke, Garcia, Jr & Ketcham, 2001). The left and right vibrations in Figure 2 are typical of those generated by a left joint reducing anteriorly displaced disk. The reduction occurs on opening as the disk returns to a more normal relationship to the condyle and produces a “clicking” sound. When the disk is displaced anteriorly, just a small portion (10 to 33%) of the vibration produced on the involved side is transmitted to the opposite side, but in opposite phase or as a “mirror image” of the original (e.g. upside down). The percentage of transfer is directly related to the direction of the displacement (Radke & Kull, 2012).

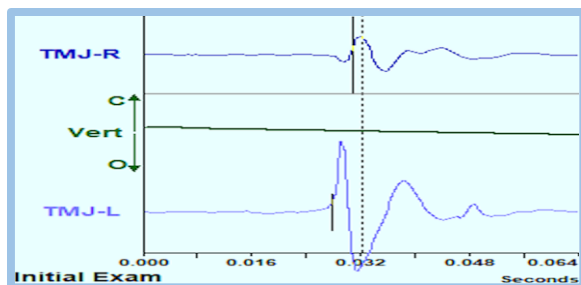


Figure 2. A typical vibration waveform from a left TMJ anteriorly displaced disk reducing during opening; a 20 % transfer.

An antero-medial disk displacement, with a greater lateral component, transmits more of the vibration to the contralateral side. The left & right vibrations in Figure 3 are typical of those generated by a very chronic left reducing antero-medially displaced disk. Since the reduction occurs on opening as the disk returns to a more normal relationship to the condyle, that is when it usually produces the audible “clicking” sound.

When the disk is displaced antero-medially, a larger portion (from about 33 % to 66 %) of the vibration produced on the left is transmitted to the right, but again in the opposite phase or as a “mirror image” of the original (e.g. upside down). The degree of antero-medial displacement is variable, since the degree of damage to the lateral attachment of the disk capsule varies.

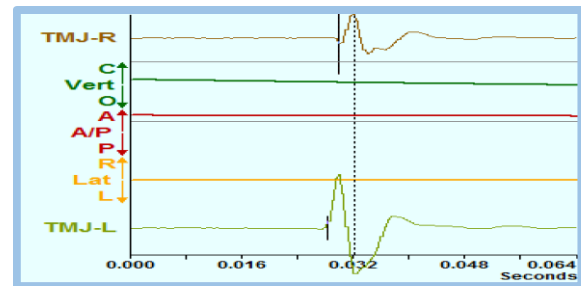


Figure 3. A left TMJ “mirror-image” vibration waveform from antero-medially displaced disk reducing during opening with a 43 % transfer.

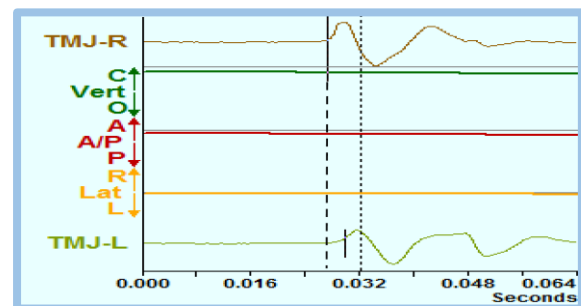


Figure 4. Right and left vibration waveforms from a right medially displaced disk reducing during opening, with an 88 % transfer.

A chronic and medially displaced disk will transfer the greatest percentage of vibration to the contralateral side. It is often the case that the reduction is not audible, except to the patient. With increasing chronicity, the intensity of the vibration is usually reduced. That is, the disk displaces and reduces with a lot less force and consequently, creates a less intense vibration. The vibrations in Figure 4 are typical of a chronic medially displaced disk reducing. The usual amount of transfer is between 66 % and 100 %.

See

The distinction between a partial or a complete disk displacement with reduction is only a matter of the intensity of the vibration. The partial disk displacement generates a vibration intensity in a 20 KPaHz to 80 KPaHz range, but complete disk displacements reduce vibrate above 80 KPaHz.

### What about manual palpation?

Palpation can be used to detect TMJ vibrations, but the vibrations occurring with one medially displacing disk will feel and even sound equally strong, as if they originate from both joints. This tends to fool the clinician, and sometimes even the patient, into believing that both left and right internal derangements are present in their joints. (Paesani, Westesson, Hatala, Tallents & Brooks, 1992) However, when there are bilateral internal derangements, JVA can demonstrate that; a) the timing is different on the right from the left for the two events, b) the vibrations do not relate to each other as a “mirror images” and c) the type or stage of each condition most often is different between the two sides.

### The 2<sup>nd</sup> type of TMJ vibration

The second common type of TMJ vibration is caused by rough surfaces (cartilage and/or bone) rubbing together and is seen when a degenerative

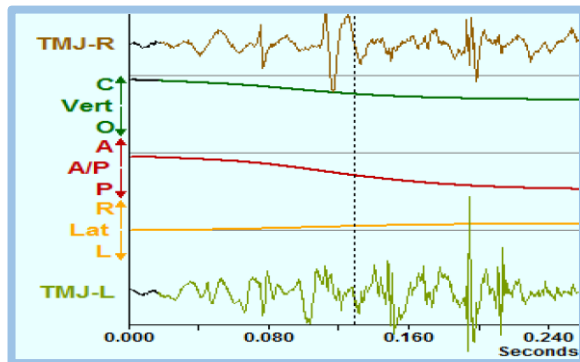


Figure 5. These are bilateral vibration example waveforms from severely degenerative TMJs. The intensities of the vibrations are low, but the durations are long, which is typical of pathology.

condition is present in the joint. (Radke & Kull, 2015; Ishigaki, Bessette & Maruyama, 1993C) The two most obvious characteristics are; 1) a

longer duration and 2) a lower intensity of the vibration. In figure 5 below, bilateral internal derangements result in severe degeneration of the joint tissues, but that is not the outcome in every case. Some patients adapt remarkably well to an internal derangement, adapting to it successfully with the result being nearly normal function. The degree of adaptation can be assessed far more definitively by including JVA dynamic testing than with just imaging alone. While imaging does clearly reveal the morphology of destruction, JVA can add to that the quality of the dynamic tissue interfaces of the joint, providing a more comprehensive evaluation (Zhang, Whittle, Wang & Murray, 2014; Christensen & Orloff, 1992). The sensitivity of JVA is such that small changes in the TMJ can be detected that do not appear on any type of imaging. An example of this is the slight roughening of the cartilage of a normal disk that is contralateral to one that is anteriorly displaced. Figure 6 shows an example of tiny vibrations emanating from the right TMJ of a patient with a left internal derangement.

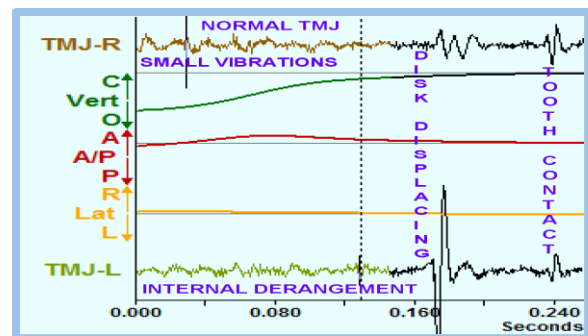


Figure 6. A left side TMJ late-displacing, early-reducing anterior Disk Displacement (ADDR) with a slightly roughened contralateral disk.

### Vibration frequency content

The frequency content of TMJ vibrations can also reveal more information about the nature of the event that is taking place within the joint. Events that are related to a disk showing hypermobility (displacing/reducing) tend to produce frequencies that are below 300 Hertz (Hz = cycles/second). (Ishigaki, Bessette & Maruyama, 1993B) While 300 Hz is not any kind of magic number, it is

convenient to use and easy to remember. Thus, the BioPAK JVA program divides the frequency spectrum into two parts (above 300 Hz and below 300 Hz), and calculates the Integral from those frequencies that fall below 300 Hertz and another separate Integral from frequencies that are above 300 Hertz.

As an example, a typical vibration frequency profile from a joint with a reducing displaced disk

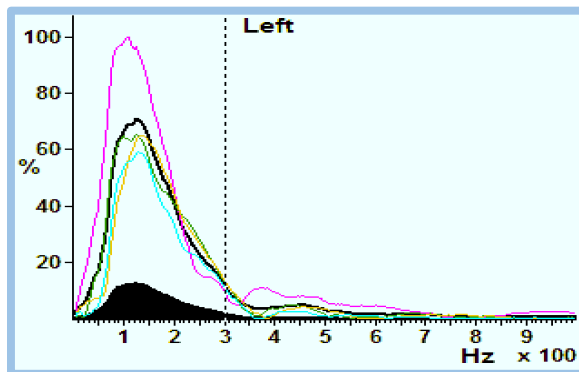


Figure 7. An example of a Fast Fourier display of the frequency content in a series of vibrations from an internally deranged TMJ during four opening movements. The thickest line is the average distribution.

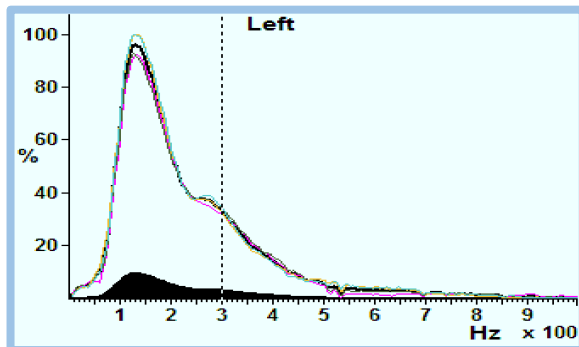


Figure 8. A patient's vibration profile with a more acute DDR condition. The Peak frequency is slightly higher at 130 Hz and the distribution extends well beyond the 300 Hz vertical dashed line. The thickest line is the average.

is shown in Figure 7. The mound shape of the distribution of energy peaks well below 300 Hz and, in fact, a majority of the energy is below the 300 Hz vertical dashed line.

The peak frequency in Figure 7 is at 126 Hz. The significance of the peak frequency is that an acute case has a higher peak frequency, but the more chronic case has a lower the peak frequency...in the absence of any degenerative changes. A more acute condition is shown in figure 8.

As a DDR condition becomes chronic and, if also well adapted, the frequency distribution becomes

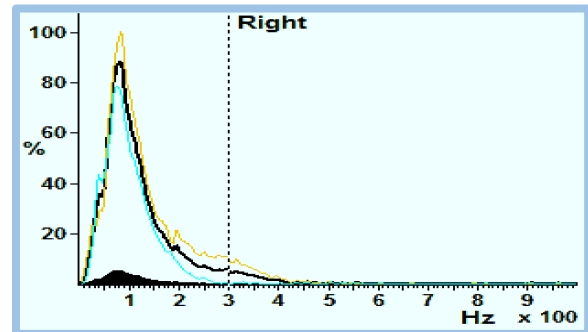


Figure 9. With successful adaptation, the reduction of the disk becomes much easier, requires less force and produces a softer vibration. This results in the distribution shifting to the left. The thickest line in this graph is the average.

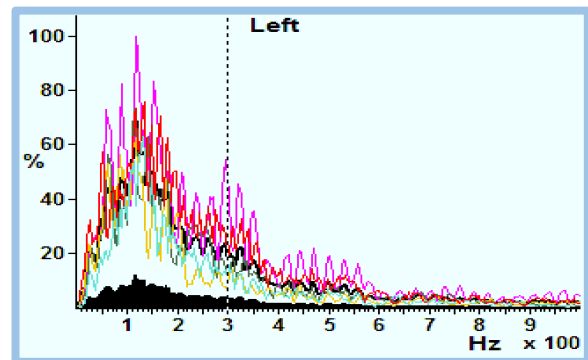


Figure 10. The presence of multiple phases of vibrations within a single analyzed event, as is common with degenerative conditions, produces a "spiky" looking FFT. This is an inherent nature of the FFT and is a good indicator that DJD is present. The thickest line is the average distribution.

narrower with mostly lower frequencies; the peak frequency falls as well. See figure 9.

The above examples are all related to TMJs with disk displacements with reduction in patients that



have not developed degenerative joint disease. In cases where degeneration occurs, the FFT pattern looks quite different, such as in Figure 10 below.

### The Ratio: $> 300 \text{ Hz} / < 300 \text{ Hz}$

For vibrations with medium or higher intensity the vibrations include some harmonic content. Harmonics are frequencies at integer multiples of the fundamental frequency (2X, 3X, etc.). It is the harmonic content that increases the bandwidth of high intensity vibrations above 300 Hz. To offset this effect we use the Ratio,  $> 300 \text{ Hz} / < 300 \text{ Hz}$ , which tends to remain more nearly constant as the intensity increases, rather than the  $> 300 \text{ Hz}$  Integral to evaluate degeneration in high intensity vibrations. Thus, for any vibrations with a Total Integral of less than 80 KPaHz, the  $> 300 \text{ Hz}$  Integral is used for assessing degeneration. For any vibration with a Total Integral greater than 80 KPaHz, the Ratio is more useful. Note: Because the human ear is far more sensitive to higher frequencies and harmonics, any TMJ noise that contains an abundance of harmonics will be very audible as a loud click or pop. That sound is an indication that the disk still fits on the condyle.

### The Median Frequency

The median frequency is the centroid or the midpoint of the bandwidth distribution of a vibration. A higher median frequency indicates more high frequencies are present. This can either be related to degenerative changes or to the acuteness of an internal derangement condition. Although the median frequency varies a lot with each type of condition, once a condition is known, the median frequency can be a sensitive way to observe small changes over time. With an internal derangement condition, the median frequency typically reduces over time as the joint adapts. However, if the joint degenerates, the median frequency will increase instead.

### Graphics Vs numerical values

The TMJ vibrations are analyzed both graphically and numerically. The graphs are a very good way to illustrate the differences in the vibrations under

different joint conditions. However, to help clinicians more quickly develop a tentative but highly probable preliminary diagnosis, the JVA Flow Chart was developed (See the Appendix).

### Jaw position at the onset of vibration

It has long been observed that an early opening reduction of the displaced disk in the TM Joint is associated with a more acute condition, whereas a late reduction is associated with a more chronic condition. When considering treatment, an early reduction is a better candidate for re-capture with an appliance. However, a late reduction indicates

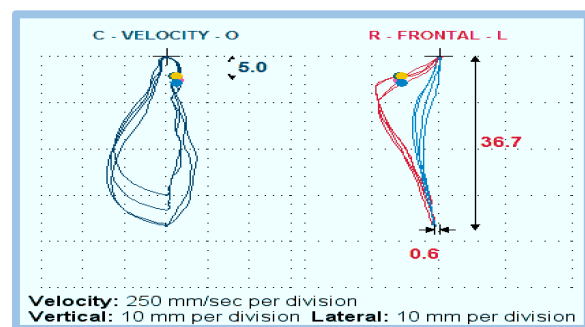


Figure 11. In this X-Y View the onset of an opening vibration occurs within the first 5 mm of opening. The colored dots indicate a very consistent position ( $\pm 1 \text{ mm}$  or so) that also supports a relatively acute condition, which is of course more amenable to recapture.

that the patient is most likely functioning “off the disk.” Functioning off the disk is one adaptive condition that resists any type of permanent re-capture, except possibly surgical. If the patient is currently functioning off the disk, pain-free and comfortable, trying to re-capture the disk is usually contraindicated. Thus, the position of the mandible at the onset of vibration can be relevant. JVA can show that position and its consistency very clearly. When JVA is used together with a jaw tracker, the precise position will be obvious.

The right joint vibration associated with figure 11 is typical of those from acute reducing anterior disk displacements; high intensity (total Integral) and including a low percentage of transfer to the contralateral joint. The presence of an immediate right lateral deviation in opening also supports a condition that is early in the overall progression

of internal derangements of the TMJ. Thus, the various JVA factors to be considered within this patient are reinforcing rather than contradicting.

## The Significance of Numerical Values

### 1. Intensity of the Vibration?

The **TOTAL INTEGRAL** is the number that best describes the intensity (or loudness) of the vibration. It sums the energy at all frequencies as a total. We then divide the full range of amplitudes into four parts:

Small Vibrations	=	0 – 20	KPaHz
Medium Vibrations	=	20 – 80	KPaHz
Large Vibrations	=	80 – 300	KPaHz
Huge Vibrations	=	300 – 1000	KPaHz

**Small Amplitude Vibrations** typically occur only in patients with; a) normal joints, b) an acute displaced disk (closed lock) condition, c) a partial disk displacement without reduction and d) the End Stage [5b] of osteoarthritis.

**Medium Amplitude Vibrations** typically occur only in patients with; a) loose capsules, b) a chronic, still-adapting disk displacement without reduction, c) a partial disk displacement with reduction, d) a chronic disk displacement without reduction with active osteoarthritis.

**Large Amplitude Vibrations** typically occur only in patients with; a) chronic well-adapted displaced disks that are reducing, b) maladapted, non-reducing, displaced disks that are especially mobile and c) eminence clicks.

**Huge Amplitude Vibrations** typically occur only in patients with; a) acute disk displacement with reduction, b) Chronic, partially-adapted disk displacement with degenerative joint disease and c) advanced degenerative joint disease with perforation of the disk or the posterior attachment tissue.

Using the JVA Flow Chart one can begin to classify the patient's condition into one of these general categories based on the Total Integrals of any vibrations that may be present.

### 2. Significance of the Range of Motion

The normal range of motion (ROM) for opening to maximum when measured at the incisors is quite large at 45 mm to 70 + mm. When an acute “closed lock” condition, the “Disk Displacement without reduction” (DD), is present, the ROM is dramatically reduced, usually into the range of 25 mm to 30 mm. If the condition is unilateral, a dramatic lateral deflection is also present towards the affected joint. This makes a clinical diagnosis of *closed lock* rather easy. X-rays and MRIs will both clearly show very limited translation of the condyle within the affected joint at the maximum open position, but are not needed for diagnosis.

The typical patient with chronic and very well adapted permanent disk displacement will regain ROM to about 36 – 42 mm. Note: By the time a non-reducing Disk Displacement (DD) becomes truly chronic and well-adapted, it is, more often than not, present bilaterally.

### 3. Significance of the Integral > 300 Hz

TMJ vibrations caused by disk movement, loose capsule, partial or complete disk displacement with reduction, (P-DDR or DDR), typically have most all of their frequency content below 300 Hz. However, large and huge vibrations do tend to produce harmonics above 300 Hz, so only the small and medium vibrations are usually tested for an absence of > 300 Hz content. When small or medium amplitude vibrations contain more than 3.0 KPaHz above the 300 Hz reference, the presence of degenerative changes within the TM joint is likely. Generally, the greater the amount of energy above 300 Hz in relation to the amount below 300 Hz, the more severe the degenerative changes. This condition is expressed as the Ratio: > 300 Hz / < 300 Hz.

### 4. Significance of the Ratio

For medium, large and huge vibrations the Ratio (> 300 Hz / < 300 Hz) is calculated and a value greater than 0.300 is considered as an indication of degeneration within a joint. The Ratio is not used when the Total Integral is less than about 20, because any random noise in the system may artificially inflate the Ratio for a very small

vibration. For very small vibrations the  $> 300$  Hz Integral is used without considering the Ratio to detect degeneration because background noise can be automatically extracted from it. The “Measure Noise” function under Options can detect all the background noise at all frequencies and then subtract it from all marked vibrations.

### 5. Using the Measure Noise function

There are two versions of Measure Noise. If JVA is recorded with the Jaw Tracker, under Options the Auto Measure Noise function can be checked and it will operate automatically whenever a trace is analyzed. See Figure 12. You only need to do this once. This is because with the Jaw Tracker recording, the program can detect when no movement occurs, either at maximum opening or when the teeth are together. When there is no movement at all, any signals present are just electrical interference.

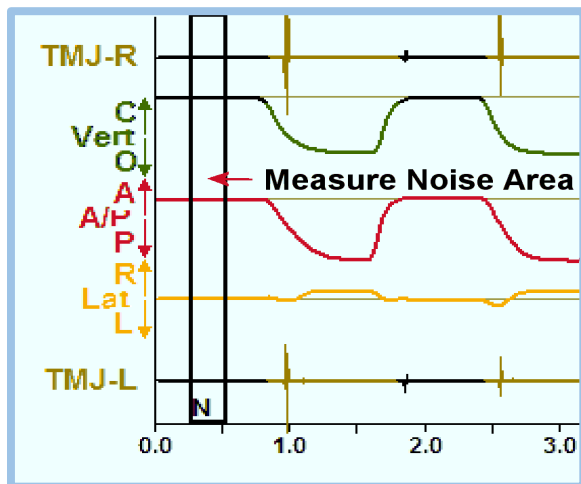


Figure 12. If the Auto Measure Noise feature is selected under Options, the BioPAK program will always place a marker with an “N” at the point where the noise is measured.

When JVA is recorded without the benefit of the Jaw Tracker, it is the operator’s responsibility to determine where in the trace the noise can safely be measured and whether any vibrations need to be noise reduced. If the intensity of the vibrations is at medium or higher levels, noise reduction is rarely needed. However, for small vibrations it is highly recommended. The Measure Noise must

be selected manually for each trace recorded without Jaw Tracking. To do this, with the JVA Sweep view active, first find a tooth contact and place the cursor just after it. See Figure 13. Then, click on the [Options], [Measure Noise]. This will invoke the function at the location you have chosen.

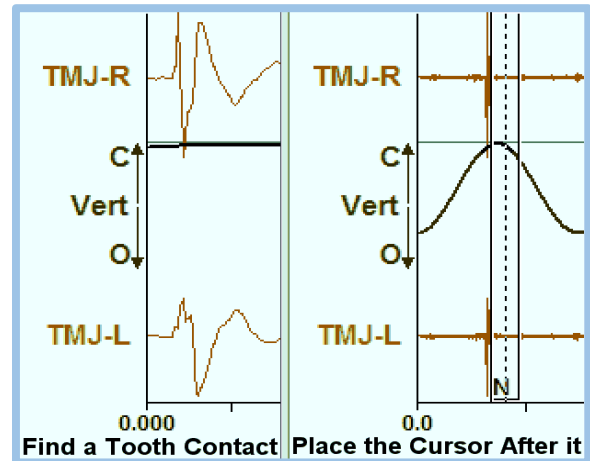


Figure 13. Find a tooth contact (look for in-phase vibrations) and place the cursor just after it, such that the tooth contacts are NOT visible in the Zoom Window. Go to Options, Measure Noise and select it. This will mark the cursor with an “N” to identify the area where the noise was measured. Then, go ahead and mark TMJ vibrations.

### The JVA Flow Chart

The JVA Flow Chart (see Appendix) can be used as a guide when analyzing a dysfunctional joint from the numeric values provided by the BioPAK program, **but it should never be used in a vacuum**. The patient history, the patient report, the clinical exam findings and the joint vibration analysis can all contribute to a clinician being able to develop a reliable and accurate diagnosis (Sharma, Crow, Kartha, McCall, Jr. & Gonzalez. (2017).

Nothing in this discussion should discourage a practitioner from obtaining sophisticated imaging when it is indicated. Images reveal morphology while JVA reveals the dynamics of joint function. These technologies complement each other rather than competing. JVA is a low-cost method that is excellent for screening patients for any internal derangements. A JVA recording that indicates a



perfectly normal or well adapted joint may save the patient the expense and inconvenience of an unnecessary MRI or the exposure to a CT scan.

### The Indications for Imaging

Currently, there are no published and universally accepted guidelines for when any type of imaging is “indicated.” Not for MRI, not for CBCT, and not for any imaging of the TMJ. This may seem ironic with the fact that “Imaging when Indicated” is very often suggested by experts. For some only pain in the TMJ is an indication. For others, a restricted ROM is also an indication. Too often TMJ noises are considered no problem or even normal. Of course, for radiologists and for at least some oral surgeons, imaging is the “Gold Standard.” Thus, in the real word, “Imaging is Indicated” whenever a clinician decides he wants it.

There are four prime factors that can be taken into consideration before prescribing imaging;

1. A history of TM joint symptoms
2. Current patient report of TMJ symptoms
3. Clinical exam indicating TM joint noises
4. JVA indicates the presence of an internal derangement and/or degeneration.

Since imaging is more expensive and/or invasive to obtain than these four, the lowest cost/benefit ratio and the least invasive approach requires “imaging when indicated” to occur after all of these other procedures have been completed first.

### Criteria needed to recapture a disk<sup>1</sup>

1. An early opening reduction vibration that has started “clicking” rather recently suggests acuteness (ask how long the patient’s been aware of the joint noise). A loud click or pop indicates that the disk retains its original shape enough to still fit the condyle. If the disk shape is altered significantly, a dull thud results instead of a loud and sharp click or pop.
2. A difficult painful reduction is another positive indication that the condition is acute (ask the patient about pain). The

acute phase varies in length from patient to patient. If the patient is highly pain-averse the acute phase will last longer as the patient will tend to be careful and very tentative in his or her masticatory movements.

3. A high Total Integral indicates the disk shape has not changed very much and that it still matches the shape of the condyle well enough to possibly be recaptured.
4. Usually, one joint is internally deranged at a time, but by the time the condition is chronic, both joints are usually involved.<sup>2</sup>
5. The disk must be displaced anteriorly rather than medially or even laterally, indicating that both the medial and lateral attachments to the condyle are still intact. If either the medial ligament and/or the lateral ligament is completely severed, no permanent non-surgical re-capture can be expected. A careful reading of the JVA data should indicate the direction of disk displacement; the percent of contralateral transfer of the reduction vibration is an indication. See Figures 2 – 4 above.
6. With early reductions, the patients should also complain about their joints popping during chewing. If the reduction occurs within the first 20 mm of opening, it will usually disturb masticatory function.<sup>3</sup>

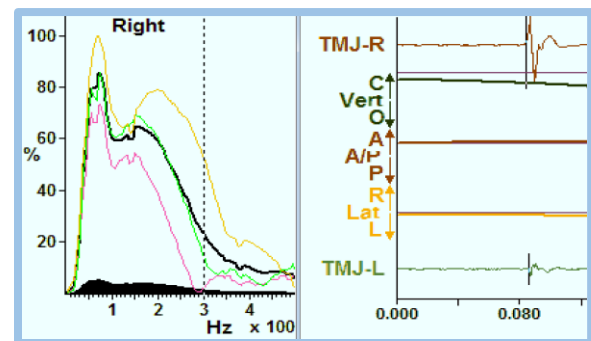


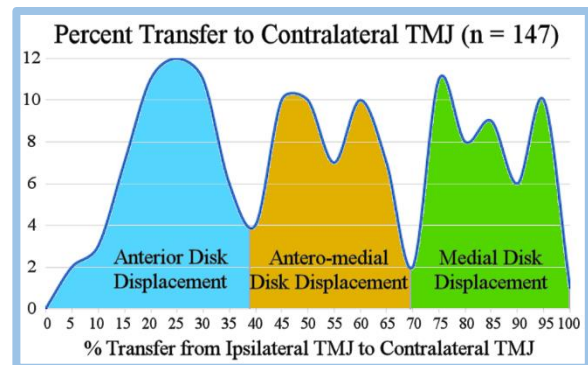
Figure 14. An acute anteriorly displaced disk with reduction vibration. The vibration is very early in opening, transfers little to the contralateral side and has a broad frequency spectrum. This is the type of vibration that can be considered for a non-surgical recapture.

## END NOTES:

1. The previous suggestions are relevant to patients that have not been treated with TMJ surgery of any kind. Surgery or even a procedure as seemingly innocuous as arthrocentesis can change the situation within the TM joint in unpredictable ways. These suggestions may or may not be applicable and any positive treatment expectations may need to be adjusted accordingly.
2. Most complete denture patients have TMJs that are degenerative. However, any new denture or permanent restorative procedure that improves the maxillo-mandibular relationship can improve the situation within the joints as well as improve the patient's ability to masticate more effectively (Goiato, Garcia, dos Santos & Pesqueira, 2010; Montgomery, Shuman & Morgan, 2010). The loss of molar support is particularly damaging to the TMJs. The restoration of posterior support allows the TMJs to adapt more successfully and recover at least partially from their damage.
3. Do orthodontists ever need to be concerned about TMJ function? Some have previously concluded that orthodontic treatment has no long-term affect upon the TMJs or the development of TMD (Harzer & Reinhardt, 1990; Hirata, Heft, Hernandez & King, 1992; Hirsch, C. (2009). Others have concluded that the quality of the treatment is the greater determinant of outcome (Owen, 1996; Kocsis & Kocsis, 1997; Spahl, 2001; van Beek, 2009). An objective assessment of the risks seems to favor a neutral relationship when high quality orthodontics is provided. However, it appears that orthodontists, who are in a position to potentially reduce the risk of developing TMD, do not take advantage of it. That is, the average orthodontic patient is no worse off after treatment, but also no better off with respect to developing TMD in the future (Swedish

Council on Health Technology Assessment. 2005).

4. The TM joints of 147 subjects with reducing displaced disks (DDR) were recorded with JVA. The percentage of joint vibration transfer from the ipsilateral joint to the contralateral joint was measured and displayed in the graph below. The distribution is 3-mounded, which supports the concept that the three most commonly found types of disk displacements are; 1) anterior, 2) antero-medial and 3) medial.



A frequency of occurrence plot of specific amounts of vibration transfer from the ipsilateral joint to the contralateral joint. The three distinct areas of the distribution are evident in this graph corresponding to the three most common types of disk displacement.

### References:

- Christensen, L. V. (1992). Physics and the sounds produced by the temporomandibular joints. Part II. *J Oral Rehabil*, 19(6), 615-27. PMID: 1469497
- Christensen, L. V. & Orloff, J. (1992). Reproducibility of temporomandibular joint vibrations (electrovibratography). *J Oral Rehabil*, 19(3), 253-63. PMID: 1500969
- Goiato, M. C., Garcia, A. R., dos Santos, D. M. & Pesqueira, A. A. (2010). TMJ vibrations in asymptomatic patients using old and new complete dentures. *J Prosthodont*, 19(6), 438-42. PMID: 20546491
- Gupta, B., Thumati, P. & Radke, J. (2016). Temporomandibular joint vibrations from totally asymptomatic subjects. *Cranio*, 34(3), 169-75. PMID: 25981345
- Harzer, W. & Reinhardt, A. (1990). Limiting factors of functional adaptation to orthodontic space closure. *Eur J Orthod*, 12(3):354-7. PMID: 2401344
- Hirata RH, Heft MW, Hernandez B, King GJ. (1992). Longitudinal study of signs of temporomandibular disorders (TMD) in orthodontically treated and nontreated groups. *Am J Orthod Dentofacial Orthop*, 101(1), 35-40. PMID: 1731485
- Hirsch, C. (2009). No Increased risk of temporomandibular disorders and bruxism in children and adolescents during orthodontic therapy. *J Orofac Orthop*, 70(1), 39-50. PMID: 19194674
- Ishigaki, S., Bessette, R. & Maruyama, T. (1993A). Vibration of the temporomandibular joints with normal radiographic imagings; comparison between asymptomatic volunteers and symptomatic patients. *Cranio*, 11(2), 88-94. PMID: 8495512
- Ishigaki, S., Bessette, R. & Maruyama, T. (1993B). Vibration analysis of the temporomandibular joints with meniscal displacement with and without reduction. *Cranio*, 11(3), 192-201. PMID: 8242781
- Ishigaki, S., Bessette, R. & Maruyama, T. (1993C). Vibration analysis of the temporomandibular joints with degenerative joint disease. *Cranio*, 11(4), 276-83. PMID: 8118898
- Kocsis A, Kocsis G. (1997). Adverse effects of orthodontic treatment. *Fogorv Sz*, 90(11):327-32. Review. Hungarian. PMID: 9424441
- Kondrat, W., Sierpinska, T. & Radke, J. (2018). Assessment of the temporomandibular joint function in young adults without complaints from the masticatory system. *Int J Med Sci*, 15(2), 161-9. PMID: 29333100
- Kondrat, W., Sierpinska, T. & Golebiewska, M. (2012). Vibration analysis of temporomandibular joints – BioJVA device description and its clinical application in dental diagnostics – review of literature. *J Stoma*, 65(2), 207-15.
- Lewis, R. P., Buschang, P. H. & Throckmorton, G. S. (2001). Sex differences in mandibular movements during opening and closing. *Am J Orthod Dentofacial Orthop*, 120(3), 294-303. PMID: 11552129
- Linde, C. & Isacson, G. (1990). Clinical signs in patients with disk displacement versus patients with myogenic craniomandibular disorders. *J Craniomandib Disord*, 4(3), 197-204. PMID: 2098396
- Montgomery, M. W., Shuman, L. & Morgan, A. (2010). Joint vibration analysis in routine restorative dentistry. *Dent Today*. 29(9), 94, 96-7. PMID: 20973423
- Owen, A. H. (1996). Rationale and utilization of temporomandibular joint vibration analysis in an orthopedic practice. *Cranio*, 14(2), 139-53. PMID: 8949869
- Paesani, D., Westesson, P. L., Hatala, M. P., Tallents, R. H. & Brooks, S. L. (1992). Accuracy of clinical diagnosis for TMJ internal derangement and arthrosis. *Oral Surg Oral Med Oral Pathol*, 73(3), 360-3. PMID: 1545969
- Radke, J., Garcia, R. Jr. & Ketcham, R. (2001). Wavelet transforms of TM joint vibrations: a feature extraction tool for detecting reducing displaced disks. *Cranio*, 19(2), 84-90. PMID: 11842869
- Radke, J. C. (1992). A computer “brain” for dentistry? *Cranio*, 10(4), 267-8. PMID: 1291098
- Radke, J. C. & Kull, R. S. (2012). Distribution of temporomandibular joint vibration transfer to the opposite side. *Cranio*, 30(3), 194-200. PMID: 22916672
- Radke, J. C. & Kull, R. S. (2015). Comparison of TMJ vibration frequencies under different conditions. *Cranio*, 33(3), 174-82. PMID: 25079855
- Salzman, B. (2018). BioPAK User Guide. *BioResearch Associates, Inc.* Milwaukee, WI USA.
- Sharma, S., Crow, H. C., Kartha, K., McCall, W. D. Jr. & Gonzalez, Y. M. (2017). Reliability and diagnostic validity of a joint vibration analysis device. *BMC Oral Health*, 17(1), 56. PMID: 28209141
- Spahl, T. J. (2001). The MAS (mandibular advancement series) difference. *Funct Orthod*. 18(4), 12-23. PMID: 11887674
- Swedish Council on Health Technology Assessment. (2005). Malocclusions and Orthodontic Treatment in a Health Perspective: A Systematic Review. *Stockholm: Swedish Council on Health Technology Assessment (SBU)*; PMID: 28876802

van Beek H. (2009). Risks of orthodontic treatment. *Ned Tijdschr Tandheelkd*, 116(6), 306-10. Review. Dutch. PMID: 19585883

Widmalm, S. E., Williams, W/ J/ & Yang, K. P. (1999). False localization of TMJ sounds to side is an important source of error in TMD diagnosis. *J Oral Rehabil*, 26(3), 213-14. PMID: 10194729

Zhang, J., Whittle, T., Wang, L. & Murray, G. M. (2014). The reproducibility of temporomandibular joint vibrations over time in the human. *J Oral Rehabil*, 41(3), 206-17. PMID: 24527845

Widmalm, S. E., Bae, H. E., Djurdjanovic, D. & McKay, D. C. (2006). Inaudible temporomandibular joint vibrations. *Cranio*, 24(3), 207-12. PMID: 16933462

### Additional Reading

Brown, D. T., Cox, L. K., Hafez, A. A. & Cox, C. F. (1998). "True normal" TMD control subjects: a rare clinical finding. *Cranio*, 16(2), 84-9. PMID: 9709562

Cox, L., Brown, D. T., Aponte, R. & Hsu, Y. T. (1999). Joint vibration analysis protocol modification: adding mandibular excursive movements. *Cranio*, 17(3), 213-20. PMID: 10650409

Devi, J., Verma, M. & Gupta, R. (2017). Assessment of treatment response to splint therapy and evaluation of TMJ function using joint vibration analysis in patients exhibiting TMJ disc displacement with reduction: A clinical study. *Indian J Dent Res*, 28(1), 33-43. PMID: 28393815

Garcia, A. R., Madeira, M. C., Paiva, G. & Olivieri, K. A. (2000). Joint vibration analysis in patients with articular inflammation. *Cranio*, 18(4), 272-9. PMID: 11202847

Honda, K., Natsumi, Y. & Urade, M. (2008). Correlation between MRI evidence of degenerative condylar surface changes, induction of articular disc displacement and pathological joint sounds in the temporomandibular joint. *Gerodontology*, 25(4), 251-7. PMID: 18312371

Huang, Z. S., Lin, X. F. & Li, X. L. (2011). Characteristics of temporomandibular joint vibrations in anterior disk displacement with reduction in adults. *Cranio*, 29(4), 276-83. PMID: 22128667

Ishigaki, S., Bessette, R. W. & Maruyama, T. (1994). Diagnostic accuracy of TMJ vibration analysis for internal derangement and/or degenerative joint disease. *Cranio*, 12(4), 241-5. PMID: 7828206

Mazzetto, M. O., Hotta, T. H., Carrasco, T. G. & Mazzetto, R. G. (2008). Characteristics of TMD noise analyzed by electrovibratography. *Cranio*, 26(3), 222-8. PMID: 18686500

Mazzetto, M. O., Hotta, T. H. & Mazzetto, R. G. (2009). Analysis of TMJ vibration sounds before and after use of two types of occlusal splints. *Braz Dent J*, 20(4), 325-30. PMID: 20069257

Olivieri, K. A., Garcia, A. R., Paiva, G. & Stevens, C. (1999). Joint vibrations analysis in asymptomatic volunteers and symptomatic patients. *Cranio*, 17(3), 176-83. PMID: 10650404

Spahl, T. J. (1994). Joint vibration analysis. Part I. *Funct Orthod*, 11(5), 5-8, 10-4. PMID: 8613107

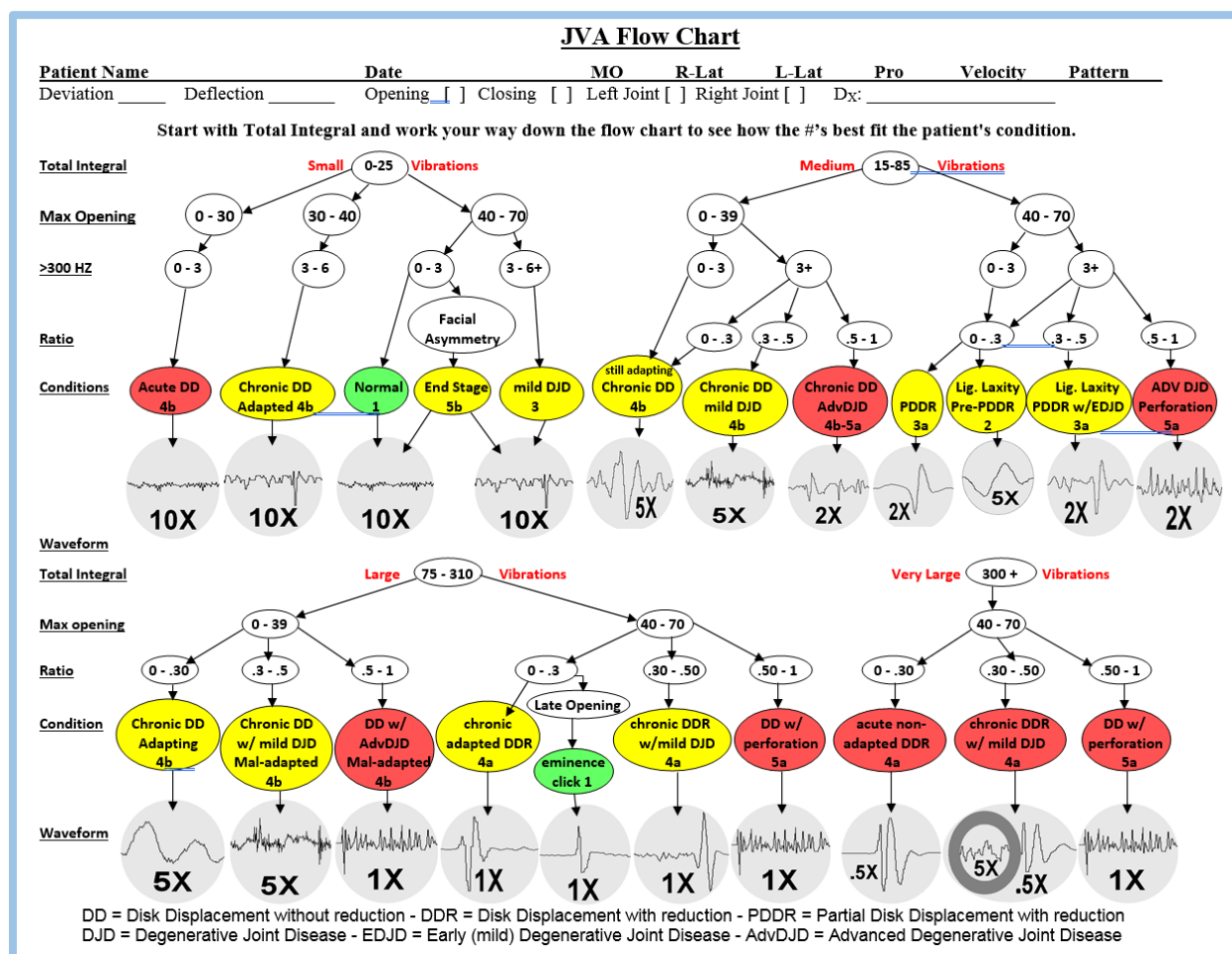
Spahl, T. J. (1995). Joint vibration analysis. Part II. *Funct Orthod*, 12(3), 4-6, 8, 10 passim. PMID: 9563316

### Key Words and Definitions

1. **Joint Vibration Analysis (JVA):** Quantitative analysis of any/all vibrations recorded from TMJ
2. **Electrovibratography (EVG):** The electronic recording and analysis of vibrations emanating from any joint, another term used for JVA
3. **Discrete Fourier Transform (DFT):** The frequency analysis of a waveform for a limited period of time during which an event occurs
4. **Frequency distribution:** Range of frequencies contained within a complex waveform
5. **Mirror-image vibration:** A discrete vibration that appears to be 180 degrees out of phase with the opposite side vibration, like an "echo" of the originating side vibration.
6. **Internal derangement:** A condition within the TMJ where the disk typically displaces to an anterior, antero-media or medial position
7. **Temporomandibular Joints (TMJ):** The joint where the mandibular condyle articulates with the temporal eminence
8. **Disk (disc or meniscal) displacement:** A disk that is out of position with respect to the condyle, with or without reduction

## Appendix to Chapter 1

The **JVA Flow Chart** was developed to assist clinicians in quickly recognizing the probable significance of specific TMJ vibrations. The relationships between these several numerical values were discovered by first training an artificial neural network from a large subject pool of JVA data recordings (Radke, 1992). This chart is not intended to provide a final definitive diagnosis, but rather an initial indication of the most likely condition within a TMJ. Further confirmation is recommended utilizing the appropriate imaging (MRI, CBCT, etc.), especially if the JVA Chart indicates a condition that appears to disagree with the patient's history and/or clinical findings.



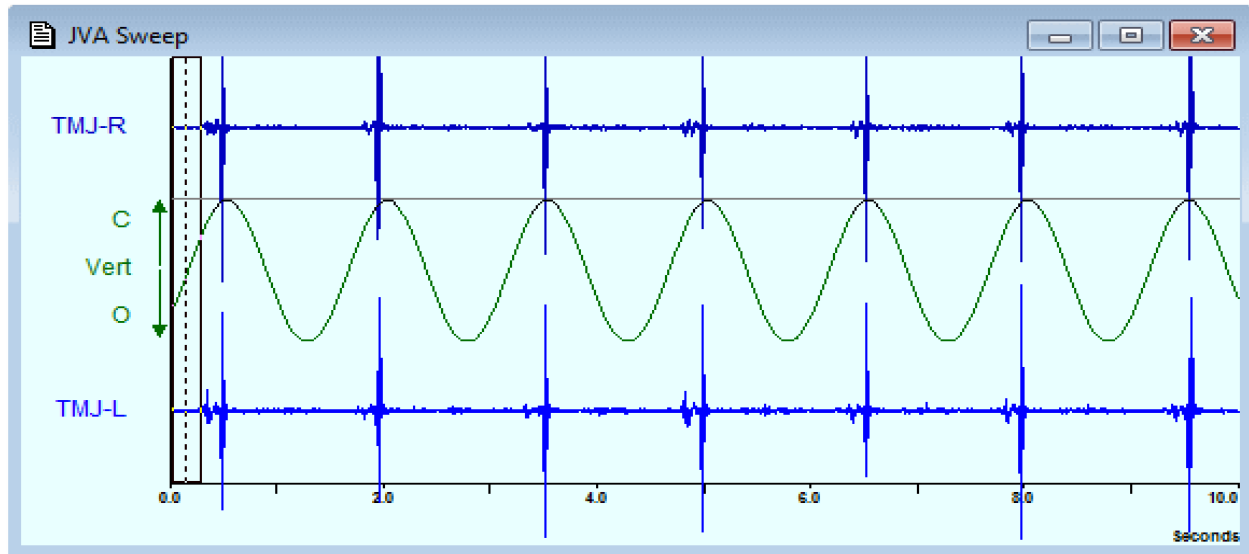
To use the JVA Flow Chart, one takes the numerical values from the BioPAK Summary Window after the vibrations in a trace have been marked. The Chart first divides the possible conditions into four groups based upon the intensity of the vibration (Total Integral). The four groups are further subdivided into 8 sub-groups based on the Range of Motion measurement. Finally, the sub-groups are further divided based on the frequency characteristics of the vibrations. The “general” appearance of the waveform is then shown as a control determination whether the correct condition has been determined. Since no two TMJ conditions are identical, every vibration has some degree of uniqueness. The sample waveforms should be taken as typical, but not as exact requirements to confirm the choice. Since there is some degree of overlap between adjacent/similar conditions, the user should consider both possibilities when the indications fall near the transition points between categories.



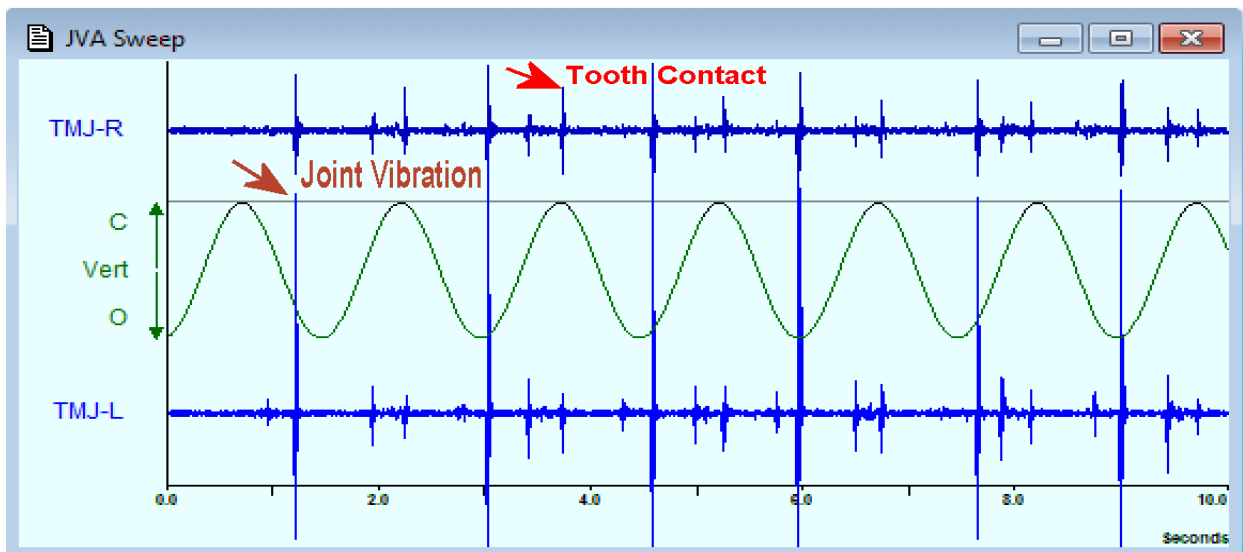
## The Mechanics of Marking JVA Records

### 1: Look for Vibrations in the JVA Sweep Window

In this screening record, without Jaw Tracking, there are bilateral tooth contact vibrations only and good timing (ROM = 50 mm, Vibrations are all at the top of each cycle, which indicates good synchronization with metronome): This is typical of Normal Joints and those that are well adapted.

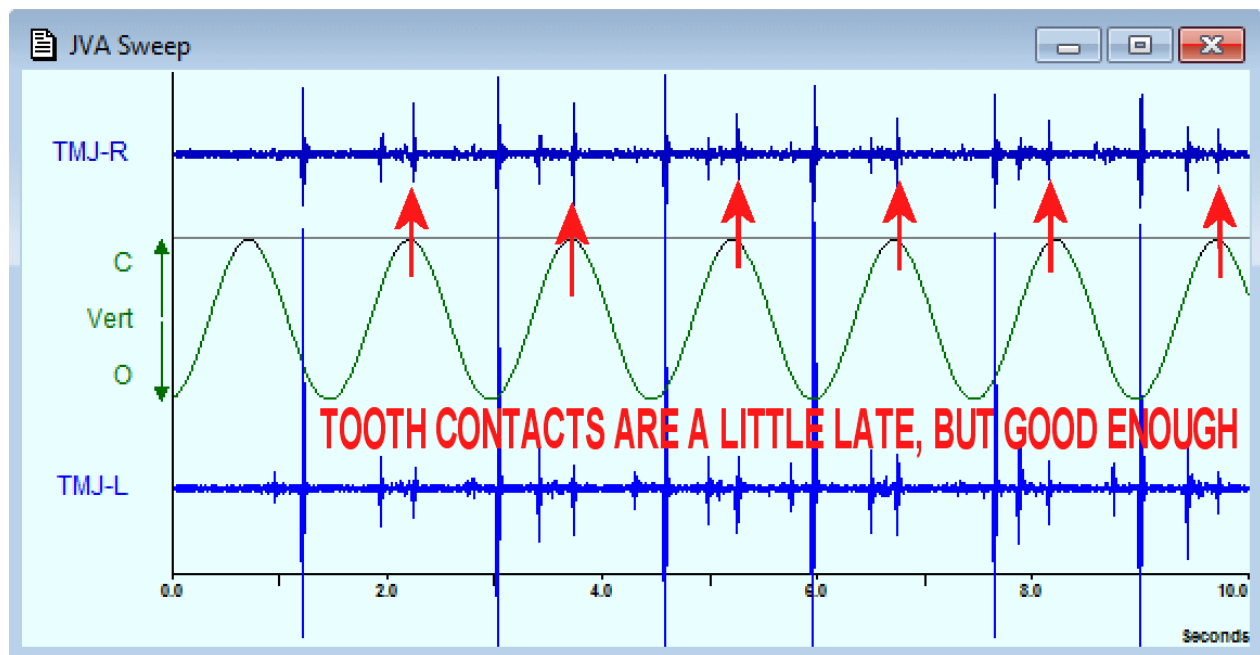


The example below has more than just tooth vibrations! However, before jumping to conclusions, always identify the Tooth Contact Vibrations first. Tooth contacts should appear at the top of each cycle. These tooth contacts are slightly late, but close enough for analysis. The ROM = 55 mm so the range of motion is right in middle of the normal range. With these big late opening Left Joint vibrations...could this be due to a "possible chronic Left DDR?"

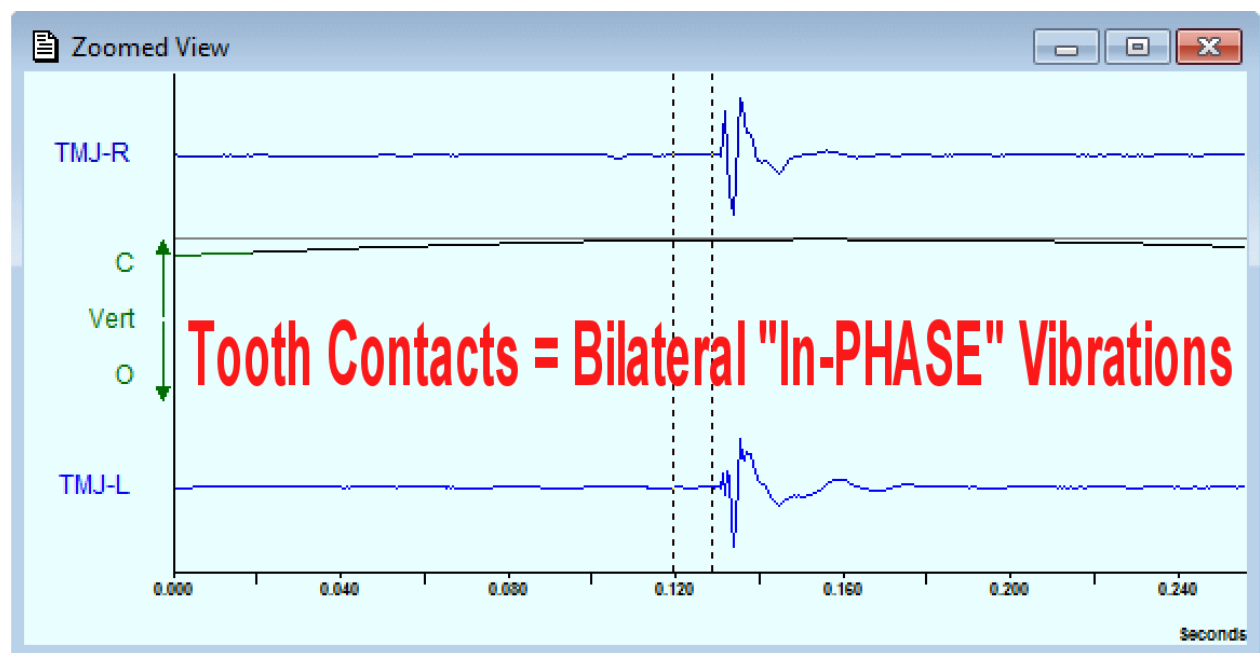


### 2: Whoa! It is necessary to identify the tooth contacts first

Click on the ZOOMED VIEW ICON and look for a fast vibration that is bilateral and "IN PHASE."



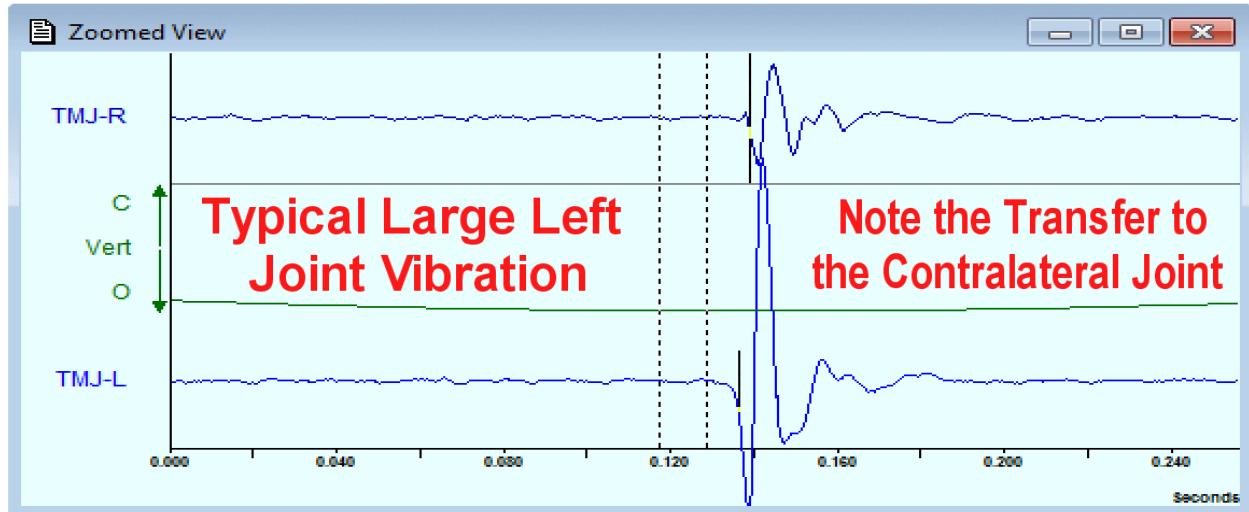
In general, if the tooth contacts are displayed a little late, any joint vibrations will also be displayed a little late (roughly the same amount). It means the real position of the joint vibration is a little bit earlier, either in opening or in closing. The image below shows bilateral tooth contacts that are “in phase,” which means the lines go up and down on the screen at the same time or in synch, rather than going in opposite directions as they do in the “mirror image” patterns associated with joint vibrations.



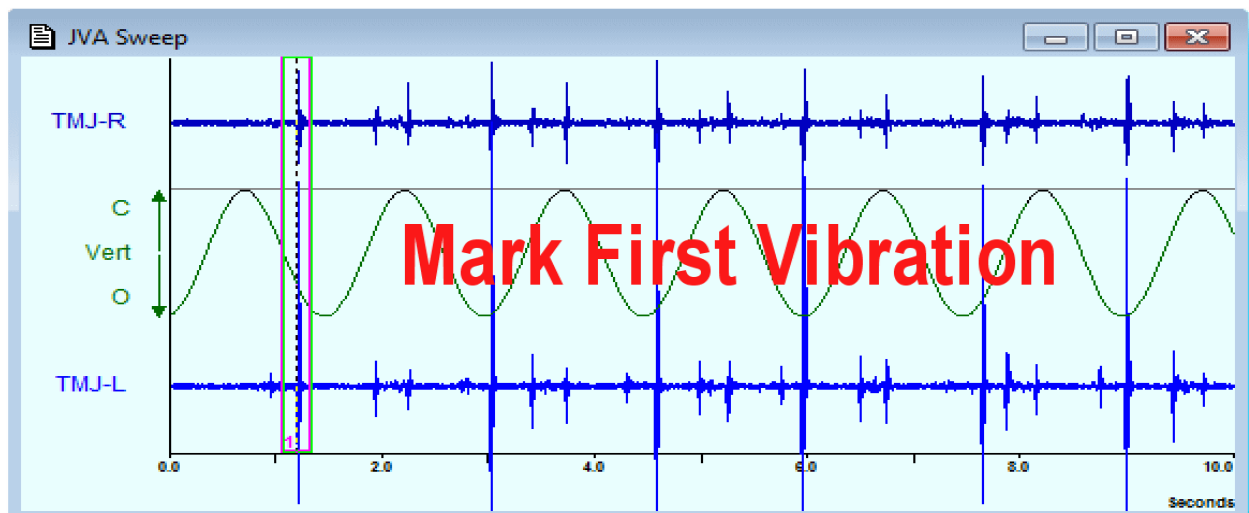
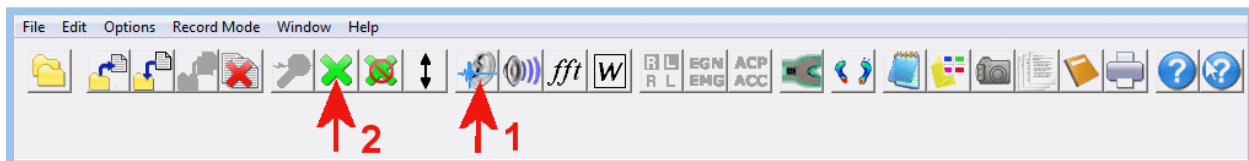### 3: After identifying the tooth contacts look for any other vibrations.

Everything except the tooth contacts will represent a joint vibration because that is the only other option. Look for the largest vibration (besides tooth contact) and view it in the ZOOMED VIEW.

Below is a large late opening left joint vibration, which transfers some vibration to the contralateral joint. Notice that the bilateral vibrations are “OUT-OF-PHASE” with respect to each other. (the left vibration is moving up on the screen while the right vibration is moving down on the screen and vice-versa). This is very commonly seen when a displaced disk is reducing during opening. It means the vibration on the right side is really the left vibration transmitted to the right and does not represent a problem on the right,

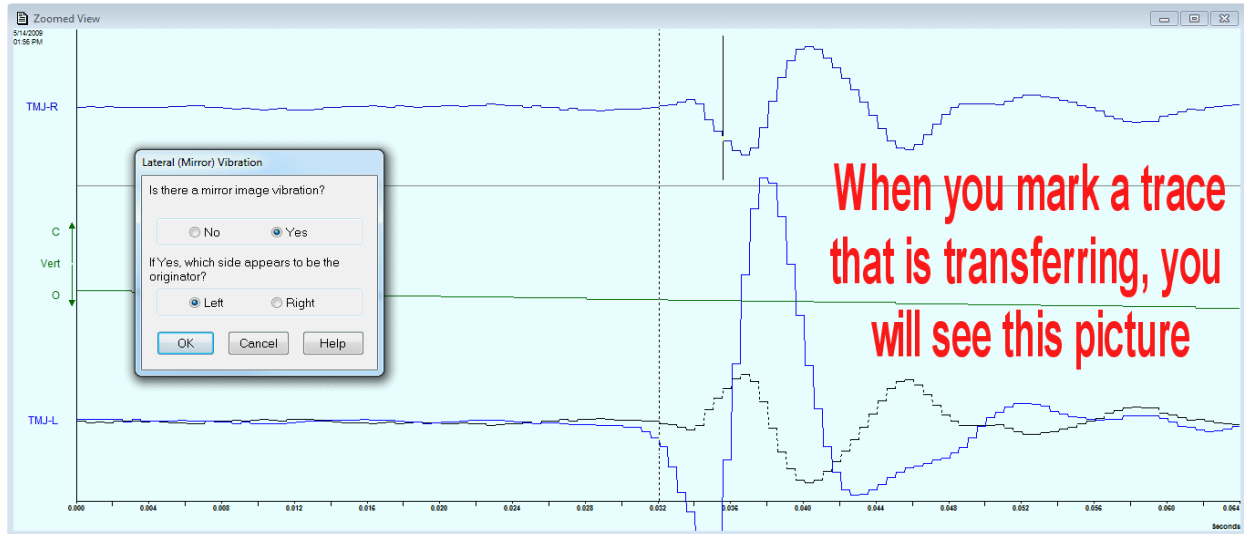


**4: To Mark the trace.** Use the “EAR” Icon to find the first of the largest vibrations and the GREEN X to Mark it. Then continue to mark additional (same event) vibrations in subsequent cycles.

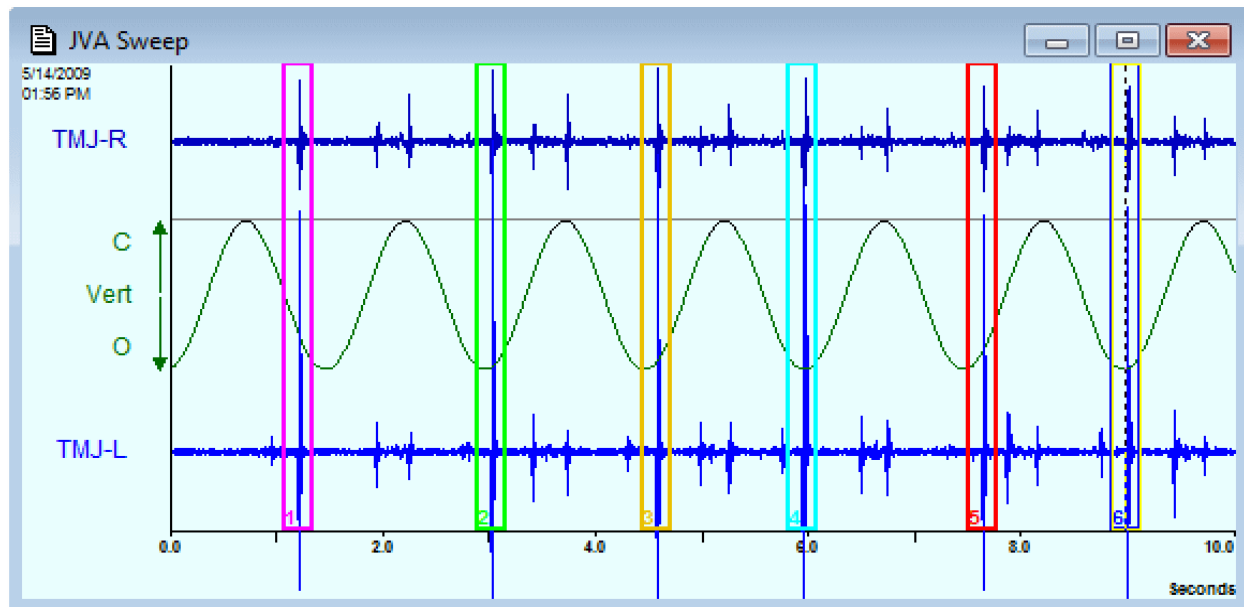


When you mark a trace and the vibration is transferring to the contralateral, the BioPAK program will ask you if you see a “Mirror Image” and which side is the “Originating Side.” Answer Yes or No and, if yes,

then select the side that starts first and usually has the larger amplitude...below it is the LEFT. Note: The “echo” side vibration will be inverted and superimposed over the originating side too. See below.



Once you have marked the first joint vibration, go ahead and mark all the rest of the same vibrations (up to 6) in successive cycles. This will produce an Average set of numerical values in the Summary Window, which will be a more accurate assessment than just randomly analyzing one individual vibration.



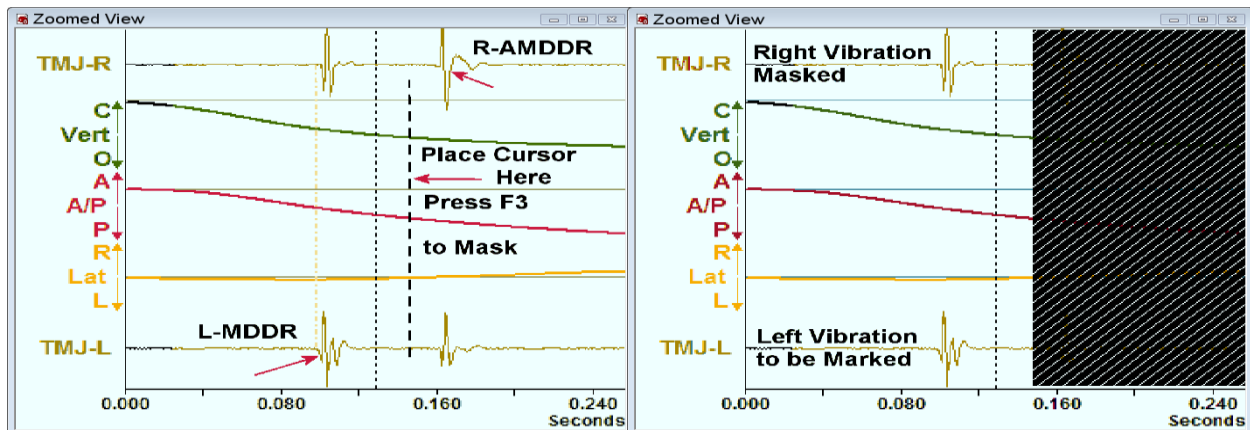
**CAUTION:** Do not mark both opening and closing vibrations. Only mark the same vibration occurring at the same point in each cycle. Most of the time the largest vibration will occur during opening. If there is more than one opening (or closing) vibration, choose the largest one and *Mask* any others that may fall within the Zoom Window (see *MASKING* which is explained below). **NOTE:** It is important that only the vibration of interest is visible within the Zoom Window when it is marked. If multiple discrete vibrations are visible within the Zoom Window when it is marked, the FFT may generate a distribution that is difficult to interpret.

These are the mechanical steps that are applied routinely to each trace regardless of the specific condition of a patient's joints. Now you can apply the numerical values in the Summary to the JVA Flow Chart.

### 5: Masking a trace

The process of masking a trace is useful especially in cases where you have bilateral DDR and the vertical dimension of the onset of the left and right joint vibrations is close to the same point. The illustration below shows an example of left medial DDR, followed by a right antero-medial DDR. To mask this trace:

1. Place the two vibrations on opposite sides of the dashed midline of the Zoomed View window.
2. To mask out the second vibration, place an additional cursor line just to the right of the midline.
3. Press F3 to implement the Mask.
4. Click on the Green X to mark this vibration, move to the next cycle and repeat this process.



### Unmasking a trace

To Unmask only one Zoomed View, place the cursor anywhere within the masked area and Press F4. To Unmask the entire trace sequence, click on the Unmark All Windows Icon (the Green X with a red circle with a slash through it). This will remove all masks and is necessary before analyzing the second vibration in the trace above.

Once the trace is fully unmasked the second (right TMJ) vibration can be assessed by first masking out the left TMJ vibration. The process is exactly the same except for the placement of the cursor, now to the left of the midline of the Zoomed View Window.

